

## Angiosome Concept in the Endovascular Management of Chronic Atherosclerotic Ischaemia of Lower Extremities in Diabetics

Ahmed Sayed<sup>a,b</sup>, Hussein Elwan<sup>a</sup>, Mostafa Elshal<sup>c</sup>, Ahmed Taha<sup>a,b</sup>

**Introduction:** The role of the angiosome theory in infrapopliteal disease is controversial. We aimed to study the impact of direct angiosomal revascularization on the outcome in the presence and absence of a complete foot arch.

**Method:** We studied consecutive patients presenting with infrapopliteal disease from February 2013 to January 2014, Rutherford categories 5&6, where only one infrapopliteal vessel was successfully revascularized. Patients were classified into the following groups: (i)DF: direct angiosome revascularization with patent foot arch, (ii)DN: direct angiosome revascularization with no foot arch, (iii)IF: indirect angiosome revascularization with patent foot arch, and (iv)IN: indirect angiosome revascularization with no foot arch. The outcome of the four groups was compared using Chi square test and ANOVA tests.

**Results:** 75 patients presented during the study period; 20 DF, 22 DN, 17 IF, & 16 IN. There were no statistical differences in age, sex, risk factors, run off vessel, or site of tissue loss. Limb salvage rates after 12 months were 95% in DF, 91% in DN, 76.5% in IF, and 44% in IN ( $p=0.0046$ ). Mean number of days till wound healing was  $72.2\pm 16.7$  in DF,  $122.9\pm 20.6$  in DN,  $229.4\pm 30.3$  in IF, and  $308.1\pm 29.6$  in IN ( $p<0.001$ ).

**Conclusion:** Group DF showed significantly better results in limb salvage and wound healing, followed by DN, IF, and lastly IN. A complete foot arch had a significant impact on clinical outcome, in addition to direct angiosomal revascularization. Future studies on the angiosome concept should include the completeness of foot arch as an important factor contributing to healing and limb salvage.

**Keywords:** angiosome - infrapopliteal angioplasty - foot arch  
<https://doi.org/10.36864/jinasvs.2020.2.009>

Copyright © 2020, The Indonesian Society for Vascular and Endovascular Surgery

JINASVS 2020;1(2):36-40

Correspondence: [dr.m.elshal@gmail.com](mailto:dr.m.elshal@gmail.com)

<sup>a</sup>M.D., Vascular Surgery Division, Kasr Alainy Hospital, Cairo University, Cairo, Egypt

<sup>b</sup>M.D., Vascular Surgery Unit, National Institute of Diabetes and Endocrinology, Cairo, Egypt

<sup>c</sup>M.Sc., Vascular Surgery Unit, National Institute of Diabetes and Endocrinology, Cairo, Egypt

### INTRODUCTION

The objective of salvage angioplasty is to restore in line flow to the foot arches if possible. Using conventional 6 Fr systems, vessels down to 3 mm diameter can be treated. The availability of low profile balloons based on 0.018 and 0.014 inch guide wire allows balloon dilatation of vessels as small as 2mm in diameter. It has been estimated that at least 15% of diabetics will develop a foot ulcer during their lifetime, 14%- 43% of whom will require amputation. The rate of major amputations among diabetic patients has decreased with the development of revascularization techniques over the last two decades, yet the risk of amputation remains more than seven times higher in the diabetic population than among non-diabetics. The widespread use of endovascular interventions in the treatment of tibial vessel disease was associated with the observation of diverse in results of wound healing despite technically successful revascularizations. Wound healing in feet manifesting by critical limb ischemia (CLI) seems better sustained by direct arterial

revascularization.<sup>1,10</sup> Others studies have reservations about acknowledging the benefits of angiosome-guided distal leg revascularization.<sup>11,12</sup> This study aims to examine the impact of direct angiosomal revascularization in the presence and absence of a complete foot arch on ischemic feet salvage and wound healing.

### METHOD

This is a prospective study of all consecutive patients treated for isolated infrapopliteal disease during the period from 01/02/2013 to 31/01/2014, where only a single infrapopliteal artery was dilated. All patients had critical lower limb ischemia (CLI); Rutherford categories (RC) 5 and 6. All patients received wound care according to a standard protocol. This included initial broad- spectrum antibiotics in addition to pre-intervention debridement and minor amputations for patients presenting with wet gangrene and/or signs of toxemia. The wounds were subsequently reassessed for possibility of limb salvage in accordance with Wagner's classification<sup>13</sup>



**Table 1.** Patients' demographic data and risk factors

	<b>Group DF</b>	<b>Group DN</b>	<b>Group IF</b>	<b>Group IN</b>	<b>p-value</b>
Age (yrs.)	64.45±6.5	61±7.43	60.5±6.48	63.5±6.4	0.25
Sex (♂:♀)	13:7	16:6	10:7	11:5	0.82
DM	17(85%)	18(81.8%)	15(88.2%)	15(93.7%)	0.74
Smoking	18(90%)	19(86.36%)	15(88.2%)	14(93.9%)	0.98
Hyperlipidaemia	16(80%)	15(68.1%)	11(64.7%)	9(56.25%)	0.48
Hypertension	17(85%)	19(86.36%)	12(70.58%)	12(75%)	0.55
IHD	9(45%)	13(59%)	7(41.17%)	7(43.75%)	0.66
CVS	5(25%)	7(31.81%)	4(23.5%)	2(12.5%)	0.59

**Table 2.** Site of tissue loss

	<b>Group DF</b>	<b>Group DN</b>	<b>Group IF</b>	<b>Group IN</b>	<b>p-value</b>
Single toe	5(25%)	7(31.8%)	2(11.7%)	3(18.75%)	0.49
Multiple toes	2(10%)	3(16.6%)	3(17.6%)	4(25%)	0.65
Sole	5(25%)	4(18.2%)	5(29.4%)	4(25%)	0.87
Dorsum	3(15%)	5(22.7%)	2(11.7%)	3(18.75%)	0.82
Heal	5(25%)	4(18.2%)	5(29.4%)	2(12.5%)	0.63

**Table 3.** Distal run off artery

<b>Artery</b>	<b>Group DF</b>	<b>Group DN</b>	<b>Group IF</b>	<b>Group IN</b>	<b>p-value</b>
Anterior tibial	8(40%)	10(46.6%)	5(20%)	7(40%)	0.67
Posterior tibial	7(33.4%)	8(33.4%)	10(66.6%)	6(40%)	0.42
Peroneal	5(26.6%)	4(20%)	2(13.4%)	3(20%)	0.78

**Table 4.** Comparison of the outcome in the four groups

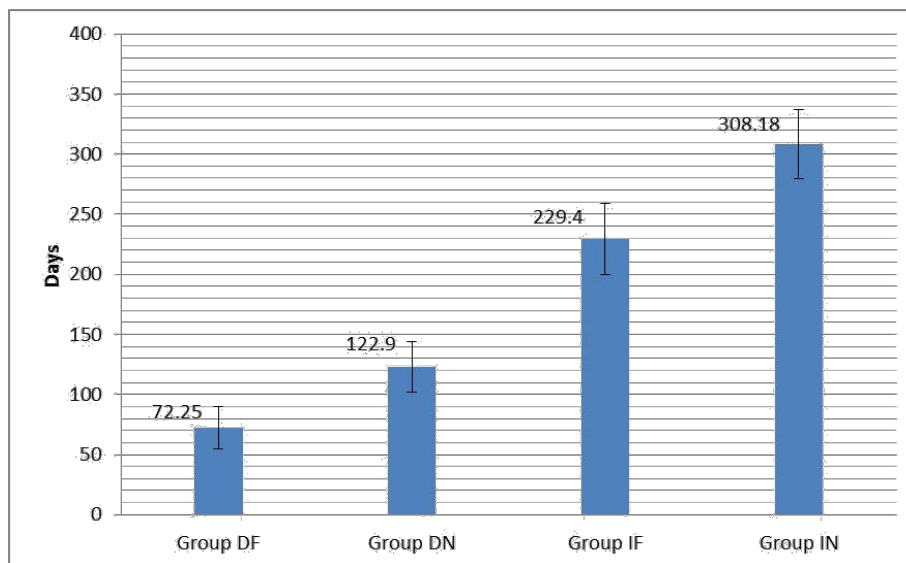
	<b>Group DF</b>	<b>Group DN</b>	<b>Group IF</b>	<b>Group IN</b>	<b>p-value</b>
Wound healing (Days)	72.2±16.7	122.9±20.6	229.4±30.3	308.1±29.6	<0.001
Amputation	1(5%)	2(9.0%)	4(23.5%)	9(56.25%)	0.0046
Death	0	1(4.5%)	3(17.6%)	6(37.5%)	0.02

and assigned according to the territory of the involved angiosome. Our policy is to treat all diseased vessels in patients with isolated infrapopliteal disease, but only those where only one vessel was amenable to revascularization are included in the study. Patients were divided into direct and indirect angiosomal revascularization according to the re-vascularized artery (target angiosome or not). Further classification was based on the presence or absence of a complete foot arch. As a result, patients were categorized into 4 groups: (i) direct revascularization with patent foot arch (DF), (ii) direct revascularization with no patent foot arch (DN), (iii) indirect revascularization with patent foot arch (IF) and indirect revascularization with no patent foot arch (IN). Revascularization was commenced within 48 hours of any prior debridement and it followed the standard techniques of infrapopliteal angioplasty, using an antegrade ipsilateral femoral access. Crossing and dilatation were performed using mainly low- profile equipment (0.018" or 0.014"). The choice of the type of endovascular intervention was left to the discretion of the operating surgeon and was also based on the patients' individual clinical status. Only patients with technically successful revascularization were included. After revascularization debridement/minor amputations were performed if needed within the following 48 hours. The wounds were photographed preoperatively and immediately post-debridement and were followed up with photographs at 3, 6, and 12 months. All wounds were classified as either fully epithelialized, granulating, or worsening in terms of enlargement of wound surface area or depth at the time of each review. Major

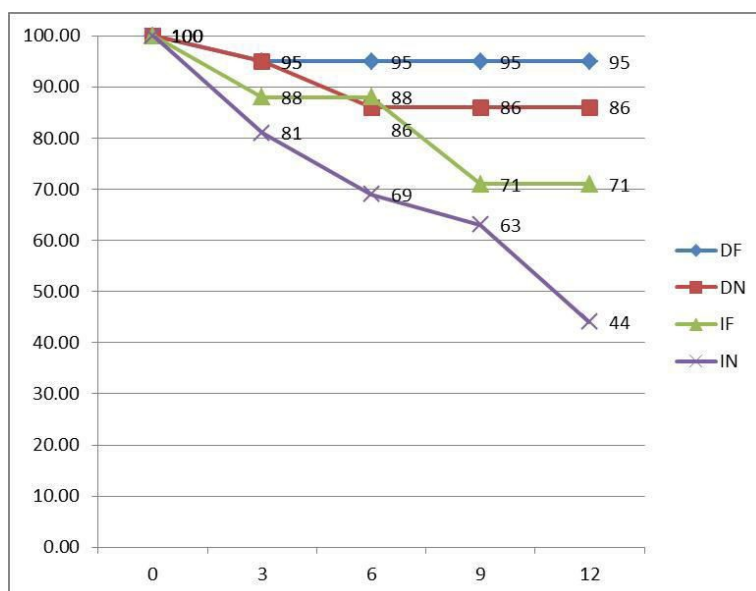
amputation was defined as amputation performed either above or below knee. All patients were followed up for at least 12 months for the endpoints of limb salvage, major amputation, or death. Groups were compared statistically using Fisher exact test for categorical variables. All analyses were conducted using SPSS for Windows, v. 16.0 (SPSS Inc, Chicago, Ill). A P value of 0.05 was considered significant.

**RESULTS**

During the study period 289 patients were treated for infrapopliteal disease. Seventy five patients were enrolled in the study, where only a single crural artery crossing the ankle was treated. In all patients the target angiosomal vessel was tackled first, and if revascularization was not possible a non-target artery was treated. Patients were distributed in the four groups as follows: 20 DF, 22 DN, 17 IF, and 16 IN. Table 1 shows demographic data and risk factors. There were no statistical differences between the four groups. Table 2 shows the site of tissue loss and table 3 compares the distal run off. There were no statistically significant differences between the 4 groups. Mean time to healing in days was least in DF (72.2±16.7days), followed by DN (122.9±20.6 days), then (229.4±30.3 days) in IF, and healing was slowest in IN (308.1±29.6 days) (p<0.001) (Fig. 1). Table 3 compares the outcome in the four groups regarding wound healing, amputations and mortality, and figure 2 compares the amputation-free survival. Group DF showed the best outcome with a single major amputation among the 20 patients, while group IN had the worst outcome with 9 amputations among



**Figure 1.** Comparison of the mean time to healing in the four groups in days ( $p < 0.001$ ).



**Figure 2.** Amputation-free survival.

16 patients. Similarly figure 2 showed best amputation amputation-free survival in group DF, followed by group DN, then group IF, and finally group IN.

**DISCUSSION**

The angiosome concept delineates the human body into three dimensional blocks of tissue fed by specific arterial and venous sources named "angiosomes." Adjacent angiosomes are connected by a vast compensatory collateral web, or "choke vessels." This concept may provide new information applicable to improving targeted revascularization of ischemic tissue lesions<sup>14</sup>. Since it was first described by Taylor and Palmer in 1987,<sup>15</sup> the angiosome concept continues to be a subject of interest to vascular surgeons. Many studies has examined this theory and mostly showing its validity. *Attinger et al* published in a detailed description of the vascular anatomy of the foot and stated that if direct angiosomal revascularization is not achievable, a certain failure rate should be predicted, unless the

surgeon can demonstrate that arterial-arterial connections between the artery to be revascularized and the source artery of the affected angiosome are open.<sup>1</sup> This study shows that presence of a complete foot arch, as well as, direct angiosomal revascularization lead to better outcome in foot revascularization. This study was designed including patients with isolated infrapopliteal disease for whom only one tibial artery was successfully revascularized. Moreover, the status of the foot arch was recorded. Depending on the revascularized vessel and status of foot arch, patients were classified into the four mentioned groups. Comparison of the age and sex revealed no significant differences between the four groups. Moreover, comparison of the risk factors as well showed no significant difference, which meant that these factors did not affect the outcome of the study, and that the results shown reflect a true difference between the four examined groups. More important was the fact that the site of lesion was similar in the four groups, which could actually have a direct confounding effect on the results if there were differences between the groups. The mean time to

healing was shortest in group DF and increased in an ascending order up to group IN. Amputations and/or limb salvage and mortality were least in group DF and worsened in the same order in the other groups. So, group DN showed worse results than DF, despite the fact that both of them were direct angiosomal revascularizations. On the other hand, group IF had better outcome than IN, despite the fact that both of them were indirect angiosomal revascularizations. This meant that the completeness of foot arch was a clearly significant factor affecting the outcome, and that direct revascularization was not the only factor leading to healing and limb salvage. Other studies comparing wound healing were mostly supporting the direct angiosomal revascularization without mentioning of the status of the foot arches. *Kabra, et al* showed ulcer healing after 6 months for direct revascularization of 96.4% versus 83.3% following indirect revascularization<sup>16</sup>. *Söderström, et al* reported ulcer healing rate of 72% at 12 months for the direct group compared with 45% for the indirect group ( $P < .001$ ).<sup>9</sup> On the other hand, Rashid et al showed better rates for healing and time to healing to be directly influenced by the quality of the pedal arch rather than the angiosome revascularized.<sup>12</sup> In 2012 our group showed in a study comparing single versus multiple tibial vessel angioplasty that there was no significant difference between both groups in limb salvage and patency.<sup>17</sup> It was not clear whether this reflected the importance of direct angiosomal revascularization or not. When Rashid et al emphasized in 2013 the importance and quality of the foot arch for healing,<sup>12</sup> their work raised the attention to the lack of reporting of the status of the foot arch in previous studies addressing the angiosome concept. Three important meta-analyses were published discussing studies examining the angiosome model.<sup>18-20</sup> Most of the studies included in the three meta-analyses showed results in favor of the angiosome concept. But the studies had so many limitations. *Biancari and Juvonen* concluded that the results suggest that, when feasible, direct revascularization may improve wound healing and limb salvage rates compared with indirect revascularization. But they mentioned that most studies were retrospective, with no enough data available to assess the comparability of the site, severity, duration, and methods of local treatment of these tissue lesions, lack of data on angiographic status of the foot arteries, and with lack of data on the feasibility of direct, angiosome-targeted revascularization in those patients who otherwise underwent indirect revascularization of the ischemic tissue lesions.<sup>18</sup> Although *Bosanquet et al* stated the results support direct angiosomal revascularization, they showed a number of limitations: (i) The absence of standardized revascularization decision-making in the included papers, especially regarding if direct or indirect revascularization was attempted, is a serious source of bias, and (ii) the target vessel revascularized was markedly different between the two groups, and outcomes may simply be a result of different vessel selection, (iii) lack of randomization.<sup>19</sup> The third meta-analysis by *Huang et al* showed similar supporting results but they recommended that future studies should report certain data in details including the wound condition and location with standard recording system, the treatment of the wound (debridement, antibiotics, and the dressing of

wound), the detail description of the stenotic status, the collateral vessels, and the condition of the pedal arch. Crucial confounding factors, such as DM, ESRD, serum albumin levels, and medications, should also be reported and analyzed. In a review by McCallum and Lane some studies showed better healing with direct revascularization while others did not. They found that the lack of consistent methodology and of randomized intervention limits generalizability from the studies reviewed.<sup>21</sup> Specific applications of angiosome guided revascularization were suggested for patients with diabetes or renal insufficiency, with ischemic tissue lesions of the lower limb, and extended large- and medium-size collateral network decay. For these cases, the concept may allow deliberate arterial reconstruction following individual wound topographies in specific ischemic areas, although deprived from "rescue-vessel" supply<sup>14</sup>. Most of our patients were diabetic but the results still do not support the "deliberate" direct revascularization as a complete pedal arch was present in two groups of the patients, and it was a significant influencing factor to the outcome beside the direct revascularization. More refined information is now available regarding the "choke vessels" that connect the foot angiosomes in specific populations, such as diabetic or renal patients with scarce collateral reserve. Identification of the importance of the foot arches, the large (0.5 mm) arterial-arterial collaterals, and the key role of metatarsal perforators has also occurred since wound-oriented vs. blind revascularization was conceived.<sup>22</sup> Our study had the advantage of being prospective not retrospective as most previous studies, and the reporting of the status of the pedal arch added important information that had a significant impact on the outcome. However, the study still continues to lack randomization, which is extremely difficult to obtain for ethical issues.

## CONCLUSION

Group DF showed significantly better results in limb salvage and wound healing, followed by DN, IF, and lastly IN. A complete foot arch had a significant impact on clinical outcome, in addition to direct angiosomal revascularization. Future studies on the angiosome concept should include the completeness of foot arch as an important factor contributing to healing and limb salvage.

## CONFLICT OF INTEREST

The author states the original work, and there is no conflict of interest in doing this research.

## ORCID ID OF AUTHORS

Ahmed Sayed

Hussein Elwan

Mostafa Elshal

Ahmed Taha

**REFERENCES**

1. Attinger CE, Evans KK, Bulan E, et al. Angiosomes of the foot and ankle and clinical implications for limb salvage: reconstruction, incisions, and revascularization. *Plast Reconstr Surg* 2006;117(7 Suppl):261S-93S.
2. Varela C, Acín F, de Haro J, et al. The role of foot collateral vessels on ulcer healing and limb salvage after successful endovascular and surgical distal procedures according to an angiosome model. *Vasc Endovascular Surg* 2010;44(8):654-60.
3. Neville RF, Attinger CE, Bulan EJ, et al. Revascularization of a specific angiosome for limb salvage: does the target artery matter? *Ann Vasc Surg* 2009;23(3):367-73.
4. Iida O, Nanto S, Uematsu M, et al. Importance of the angiosome concept for endovascular therapy in patients with critical limb ischemia. *Catheter Cardiovasc Interv* 2010;75(6):830-6.
5. Iida O, Soga Y, Hirano K, et al. Long-term results of direct and indirect endovascular revascularization based on the angiosome concept in patients with critical limb ischemia presenting with isolated below-the-knee lesions. *J Vasc Surg* 2012;55(2):363-70.e5.
6. Iida O, Takahara M, Soga Y, et al. Worse limb prognosis for indirect versus direct endovascular revascularization only in patients with critical limb ischemia complicated with wound infection and diabetes mellitus. *Eur J Vasc Endovasc Surg* 2013;46(5):575-82.
7. Iida O, Takahara M, Soga Y, et al. Impact of angiosome-oriented revascularization on clinical outcomes in critical limb ischemia patients without concurrent wound infection and diabetes. *J Endovasc Ther* 2014;21(5):607-15.
8. Alexandrescu V, Vincent G, Azdad K, et al. A reliable approach to diabetic neuroischemic foot wounds: below-the-knee angiosome oriented angioplasty. *J Endovasc Ther* 2011;18(3):376-87.
9. Söderström M, Albäck A, Biancari F, et al. Angiosome-targeted infrapopliteal endovascular revascularization for treatment of diabetic foot ulcers. *J Vasc Surg* 2013;57(2):427-35.
10. Spillerova K, Biancari F, Leppaniemi A, et al. Differential Impact of Bypass Surgery and Angioplasty on Angiosome-Targeted Infrapopliteal Revascularization. *European Journal of Vascular and Endovascular Surgery* 2015;49(4):412-19.
11. Azuma N, Uchida H, Kokubo T, et al. Factors influencing wound healing of critical ischaemic foot after bypass surgery: is the angiosome important in selecting bypass target artery? *Eur J Vasc Endovasc Surg* 2012;43(3):322-8.
12. Rashid H, Slim H, Zayed H, et al. The impact of arterial pedal arch quality and angiosome revascularization on foot tissue loss healing and infrapopliteal bypass outcome. *J Vasc Surg* 2013;57(5):1219-26.
13. Wagner FW. The diabetic foot. *Orthopedics* 1987;10 (1):163-72.
14. Alexandrescu V, Soderstrom M, Venermo M. ANGIOSOME THEORY: FACT OR FICTION? *Scandinavian Journal of Surgery* 2012;101(2):125-31.
15. Taylor GI, Palmer JH. The vascular territories (angiosomes) of the body: experimental study and clinical applications. *Br J Plast Surg* 1987;40(2):113-41.
16. Kabra A, Suresh KR, Vivekanand V, et al. Outcomes of angiosome and non-angiosome targeted revascularization in critical lower limb ischemia. *J Vasc Surg* 2013;57(1):44-9.
17. Sayed A, Taha A, Elkholy M, et al. Tibial angioplasty in diabetic patients: should all vessels be treated? *Int Angiol* 2012;31(3):239-44.
18. Biancari F, Juvonen T. Angiosome-targeted Lower Limb Revascularization for Ischemic Foot Wounds: Systematic Review and Metaanalysis. *European Journal of Vascular and Endovascular Surgery* 2014;47(5):517-22.
19. Bosanquet DC, Glasbey JCD, Williams IM, et al. Systematic Review and Meta-analysis of Direct Versus Indirect Angiosomal Revascularisation of Infrapopliteal Arteries. *European Journal of Vascular and Endovascular Surgery* 2014;48(1):88-97.
20. Huang TY, Huang TS, Wang YC, et al. Direct Revascularization With the Angiosome Concept for Lower Limb Ischemia: A Systematic Review and Meta-Analysis. *Medicine (Baltimore)* 2015;94(34):e1427.
21. McCallum JC, Lane JS. Angiosome-directed revascularization for critical limb ischemia. *Semin Vasc Surg* 2014;27(1):32-7.
22. Alexandrescu VA. Commentary: myths and proofs of angiosome applications in CLI: where do we stand? *J Endovasc Ther* 2014;21(5):616-24.